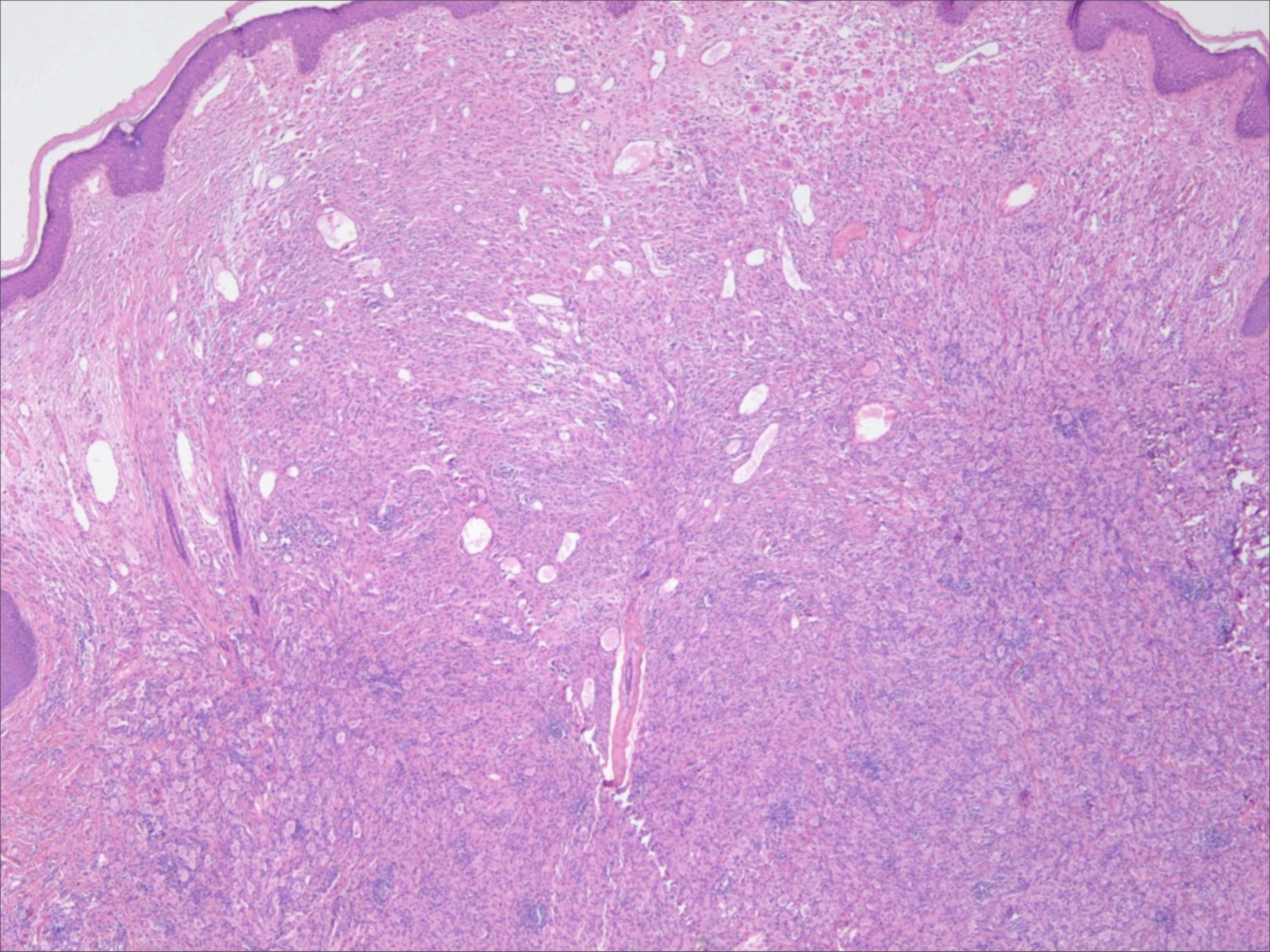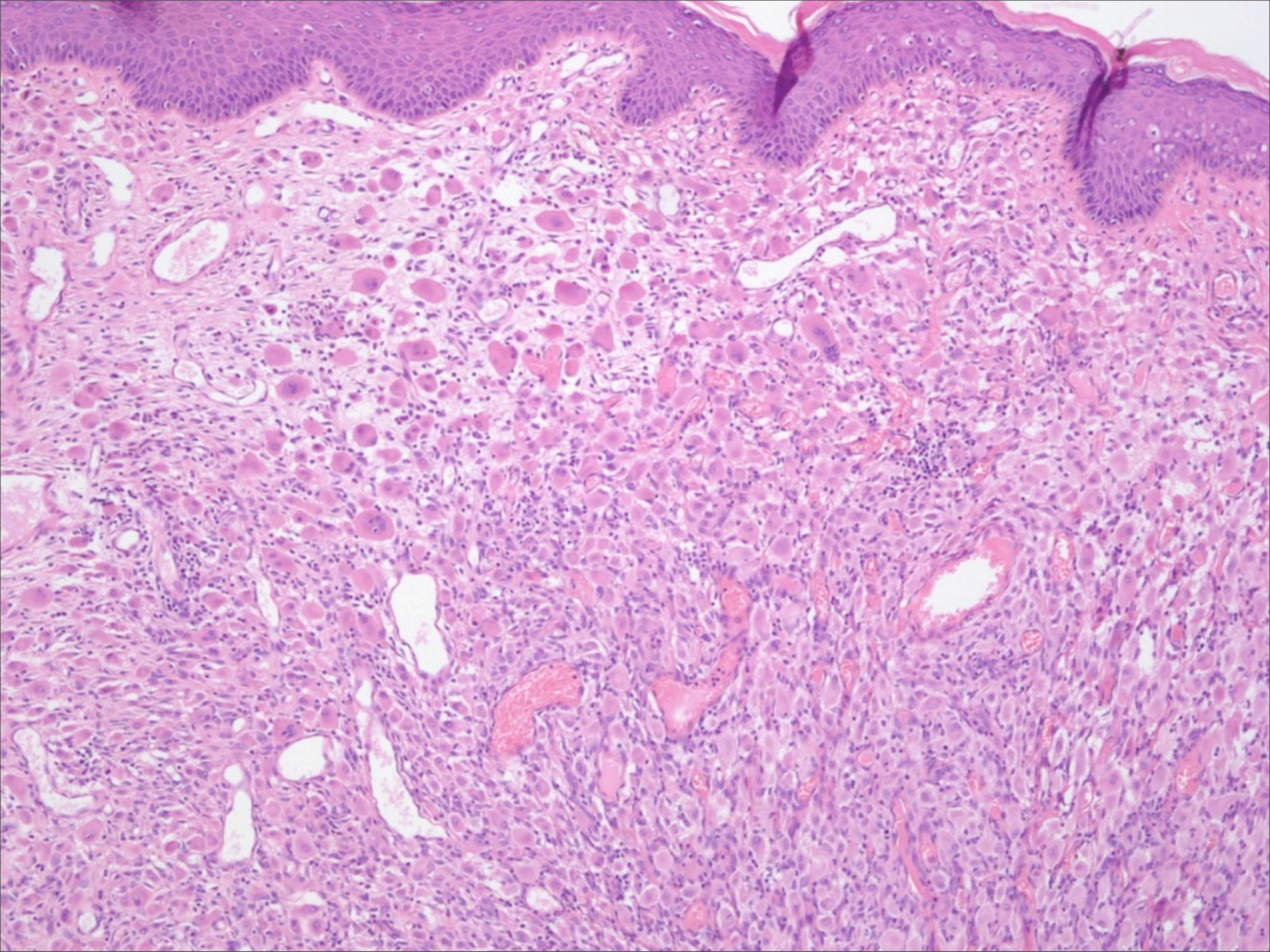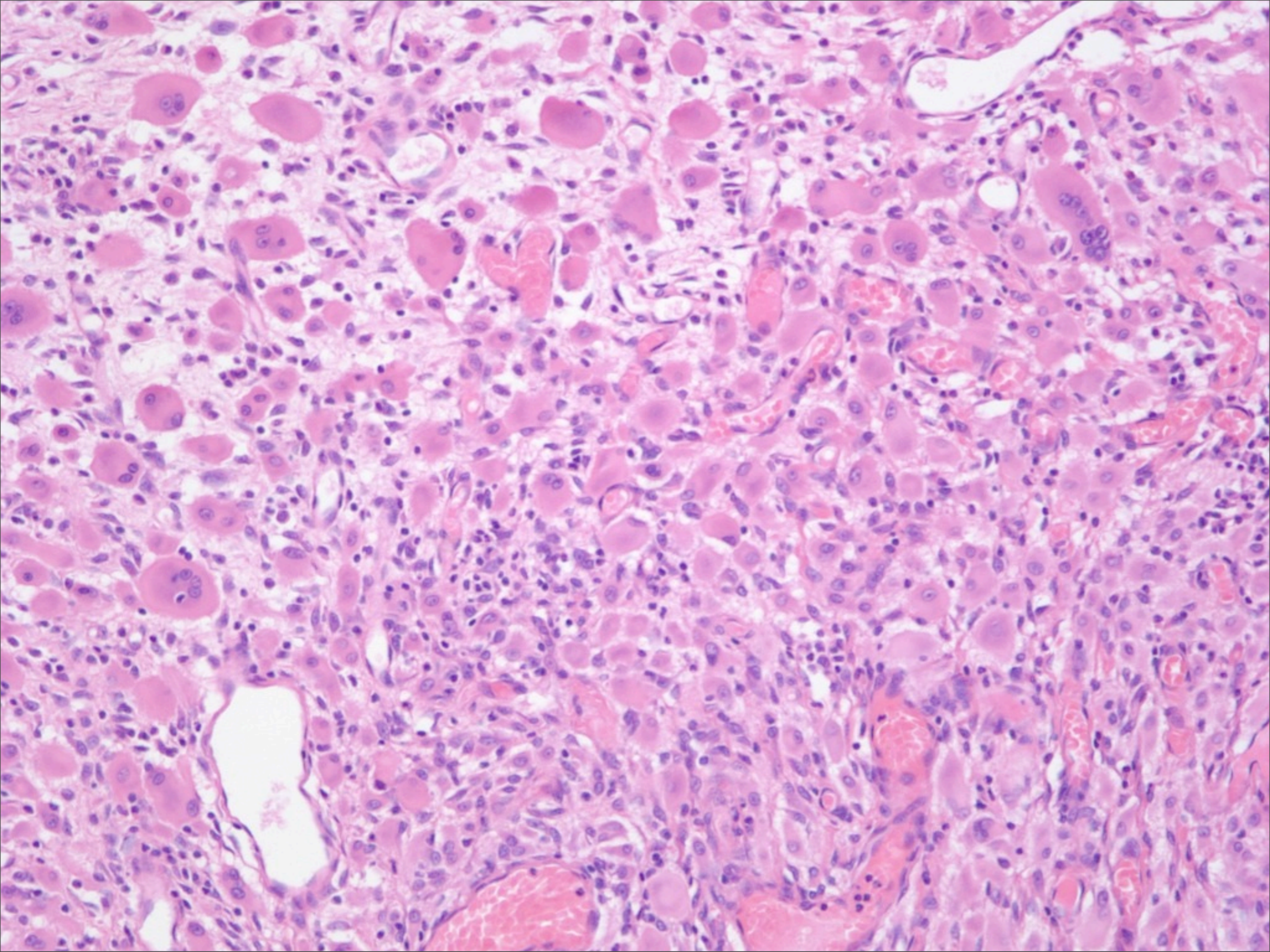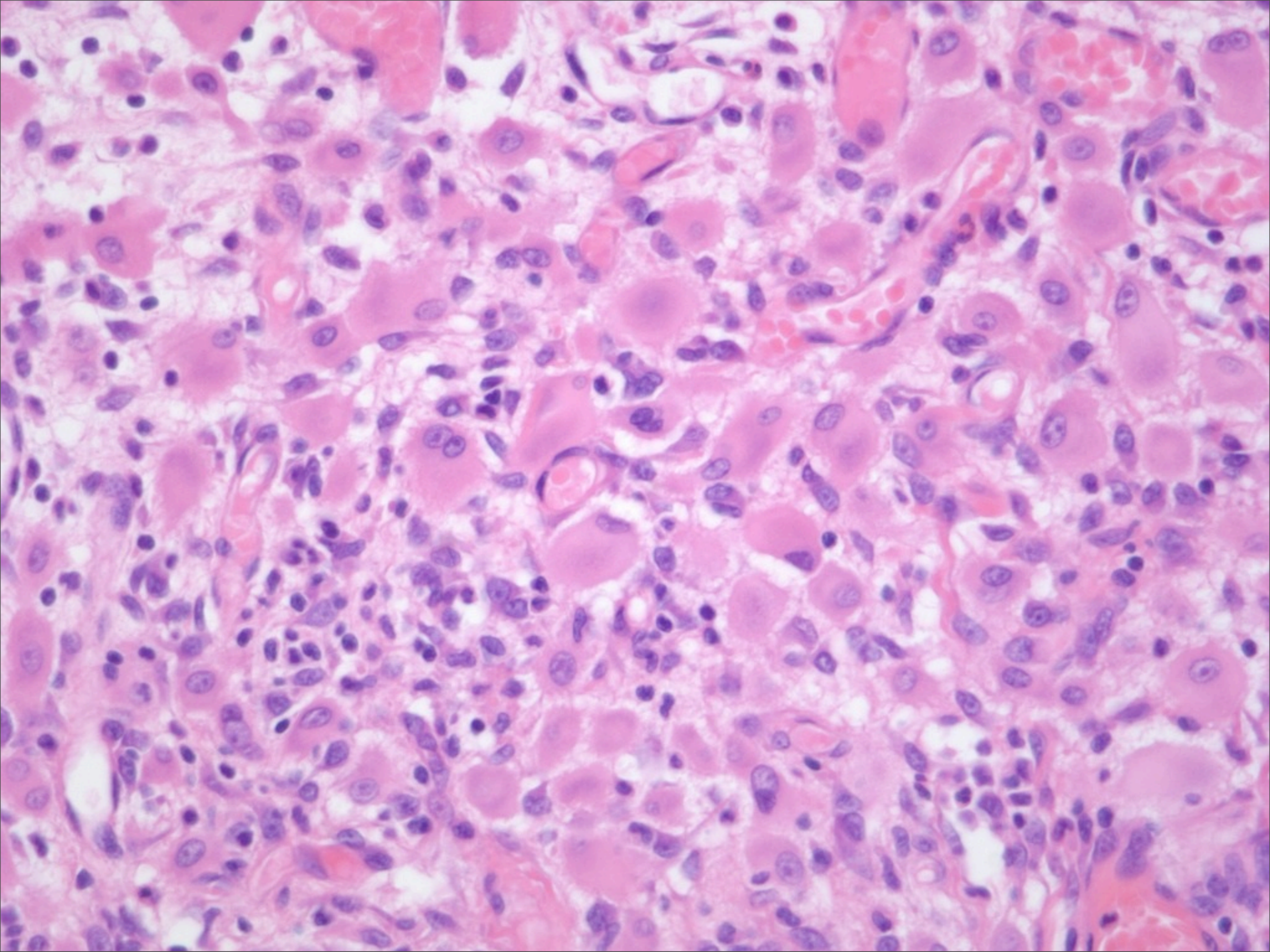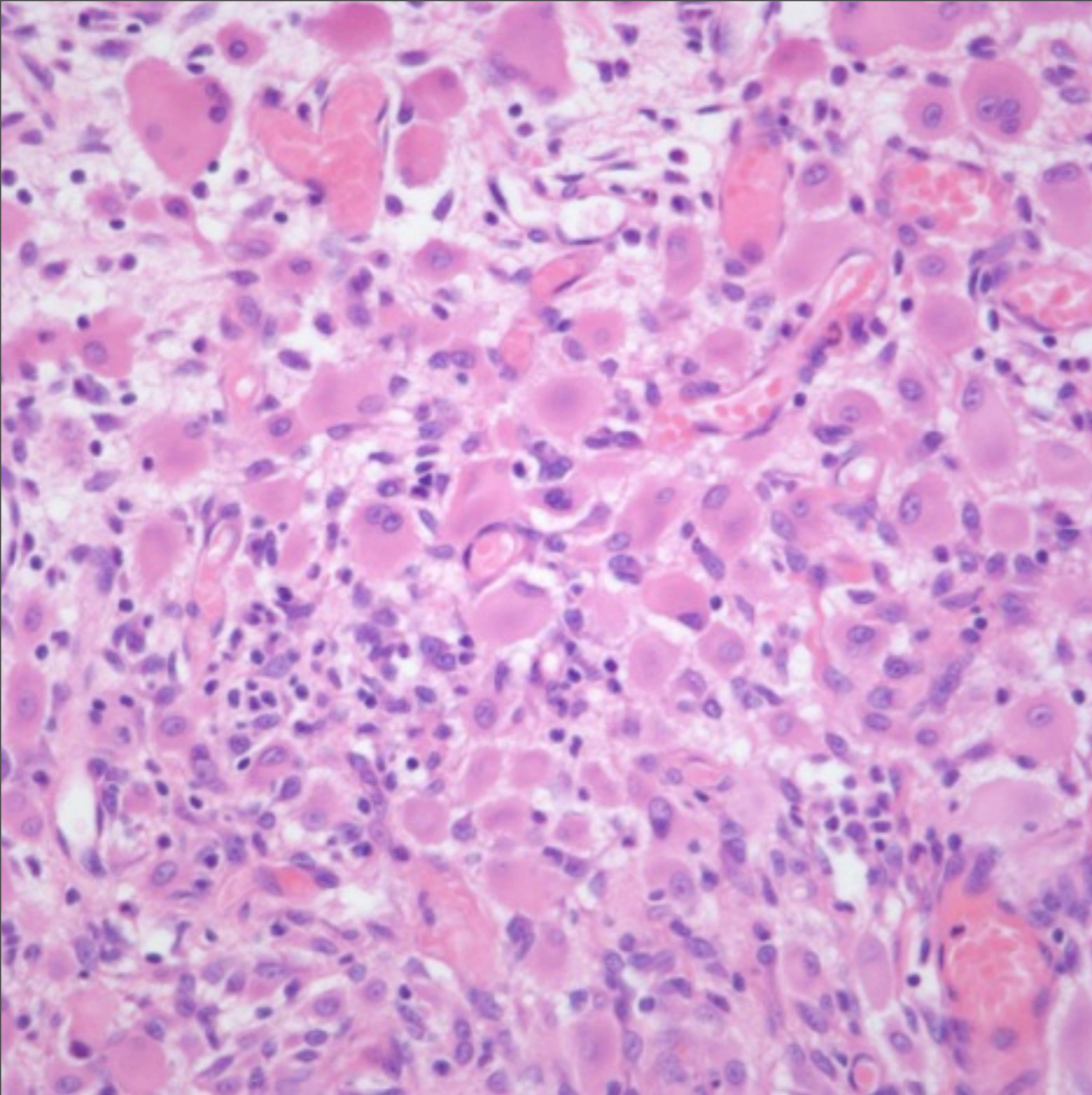


# Reticulohistiocytoma



May confirm with  
immunostains-CD68+

Background with variable  
foamy histiocytes  
and chronic inflammation

Epithelioid Histiocytes with  
Abundant eosinophilic staining cytoplasm